

# Case Report: Squamous Cell Carcinoma and THC-Rich Cannabinoid Oil

Suzanne Sisley, MD

President and Principal Investigator, Scottsdale Research Institute, Phoenix, Arizona

Carlos F. Rodriguez, MD

Dermatopathologist and Mohs Surgeon, Ironwood Dermatology, Tuscon, Arizona

Jahan Marcu, PhD

Editor in Chief, *American Journal of Endocannabinoid Medicine*, and Founding Partner, Marcu & Arora  
New York, New York

## ABSTRACT

**INTRODUCTION:** Topical treatment of cutaneous squamous cell carcinoma in situ (SCCis) is commonly employed in patients who are not suitable candidates for surgical intervention. The most commonly used topical medications include fluorouracil (5-FU) and imiquimod. To our knowledge, the use of topical delta-9-tetrahydrocannabinol (THC)-rich cannabinoid oil for the treatment for SCCis has not previously been reported in the literature.

**CASE REPORT:** We describe a case of pretibial SCCis in a geriatric patient. Surgical excision, electrodesiccation and curettage, photodynamic therapy, cryotherapy, imiquimod, and 5-FU were discussed with the patient, but declined. Topical THC oil was applied to her lesion

twice daily for 4 weeks. At the patient's 14-month follow-up visit, a biopsy revealed changes most consistent with a lichenoid keratosis, indicating the SCCis had regressed. Three years post-treatment, the patient has had no further application of THC oil and the lesion remains benign.

**CONCLUSION:** Topical treatment of THC-rich cannabinoid oil may be an effective treatment for selected cases of SCCis. Its minimal side-effect profile and ability to induce cancer cell apoptosis and inhibit angiogenesis make it an attractive option for cutaneous skin cancers. Large studies are required to clearly define the role, efficacy, and applicability of a cannabis-based oil on SCCis.

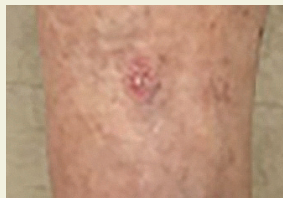## Introduction

With the rising incidence of non-melanoma skin cancer, there is a need for exploring alternative and noninvasive treatment options.<sup>1</sup> Estimates show that about 3% to 5% of squamous cell carcinoma in situ (SCCis) cases, also known as Bowen's disease,

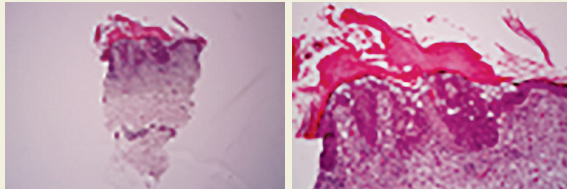
progress to invasive disease. A retrospective analysis of 239 patients concluded that although excisional surgery treatments often are chosen, less invasive methods are sometimes preferred over surgery and are especially needed in patients >65 years of age.<sup>2</sup> Direct excision or surgery has limitations and is dependent on a number of factors, including the number of lesions, location of lesions and whether they occur at suitable sites for surgery, and patient comorbidities where an aggressive treatment modality may pose significant risk (eg, a geriatric patient population).

---

*Drs. Rodriguez and Sisley have no financial conflicts of interest to disclose. Dr. Marcu provides consulting, advising, and education services to licensed cannabis operators, private companies, regulatory bodies, and universities. He serves on the PAX Health Advisory Board and as an advisor to Navigator Genomics.*



**FIGURE 1.** Scaly pink plaque measuring 1.2 cm on the right pretibial skin.



**FIGURE 2.** Punch biopsy specimen showing squamous cell carcinoma in situ.

Multiple treatment options for SCCis are available, including surgical excision, electrodesiccation and curettage (ED&C), Mohs micrographic surgery, photodynamic therapy (PDT), radiation therapy, and topical medications.<sup>2,3</sup> Two widely used topical treatments for SCCis are fluorouracil (5-FU), an inhibitor of DNA synthesis, and imiquimod, an activator of anti-tumor immunity.<sup>3,4</sup> Retrospective studies on Bowen's disease are limited and at present no treatment modality is clearly considered superior, as successful treatment of SCCis depends on a number of factors. In this report we present a case of SCCis treated with topical delta-9-tetrahydrocannabinol (THC) oil, that was associated with spontaneous remission.

### Case Presentation

An 80-year-old woman presented to our clinic with a scaly pink plaque measuring 1.2 cm on the right pretibial skin (Figure 1). The patient was in good health and reported not taking any medications besides a vitamin B complex. Before her visit, the patient had undergone a 3-mm punch biopsy by a physician at another center and received a diagnosis of SCCis (Figure 2). Treatments including surgical excision, ED&C, PDT, cryotherapy, imiquimod, and 5-FU were discussed but the patient ultimately declined, and chose THC-rich cannabinoid oil as a treatment option. This topical oil contained 44% THC, with <1% concentration of other cannabinoids as indicated per laboratory testing of the cannabidiol product (Figure 3). Terpenes, which are thought to have synergistic effects with THC, were not measured at the time of potency analysis.<sup>5</sup>

The patient applied THC oil twice daily for 4 weeks (Figure 4A and B), and kept the lesion covered with a bandage (Figure 4C). She returned to our clinic 14 months after her

initial visit, and a 1-cm faint pink macule persisted at the biopsy site (Figure 5). A second biopsy was performed at that time and revealed changes most consistent with a lichenoid keratosis (LK; Figure 6), indicating that the SCCis had regressed. One small focus of partial-thickness epidermal atypia was identified, leaving remnants of an interface reaction as seen in LK.

At article publication, 3 years after remission, the patient continues to remain cancer free, with no further application of the THC oil. The lesion has remained benign.

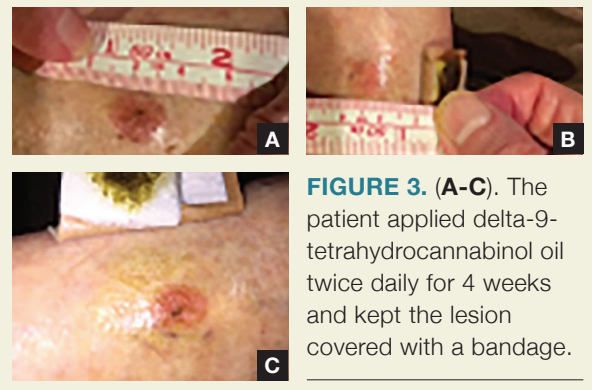
### Discussion

The majority of SCCis are treated through surgical excision, cryotherapy, topical medications, and biopsy.<sup>2</sup> Biopsy alone has been shown to induce tumor regression, but given the 1.2-cm lesion in this patient, the 3-mm punch biopsy performed would be unlikely to eliminate the entire lesion.<sup>6</sup>

The use of medical cannabinoids in the field of medicine has steadily increased in recent years. Cannabis and related compounds are most commonly used to alleviate nausea and stimulate appetite in patients undergoing chemotherapy.<sup>7</sup> Some studies have shown success in patients with multiple sclerosis and chronic pain.<sup>8</sup> Exogenous use of cannabinoids as a potential treatment for cutaneous skin cancers has been studied in experimental models with results indicating promising effects.<sup>9,10</sup>

~~Cannabis, an endocannabinoid, is a G protein-coupled receptor bound to endogenous ligands.~~ THC has been shown to function through 2 known receptors, cannabinoid receptor types 1 and 2 (CB<sub>1</sub> and CB<sub>2</sub>). CB<sub>1</sub> receptor is expressed mostly in the brain, whereas CB<sub>2</sub> receptor is expressed mainly in the immune system.<sup>11</sup> Medical cannabinoids also can modulate immune function and apoptosis induction, similar to imiquimod.<sup>12</sup>

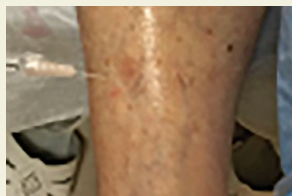Cannabis is thought to be effective against cutaneous skin cancers due to the ability of THC to induce cancer cell apoptosis and inhibit angiogenesis.<sup>13</sup> Unlike other topical treatments for the treatment of SCCis, cannabinoids generally are well



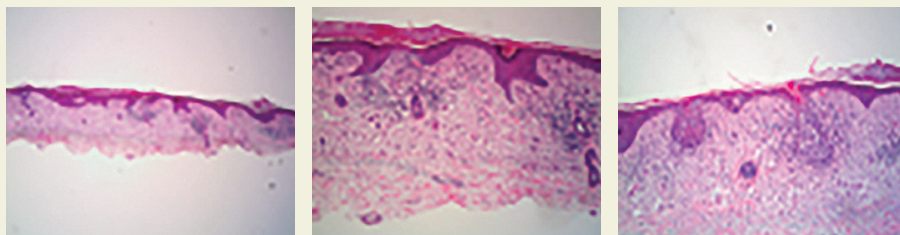
**FIGURE 3. (A-C).** The patient applied delta-9-tetrahydrocannabinol oil twice daily for 4 weeks and kept the lesion covered with a bandage.

## Squamous Cell Carcinoma

continued from page 25



**FIGURE 5.** Post-treatment with topical cannabidiol containing 44% delta-9-tetrahydrocannabinol, with <1% concentration of other cannabinoids. At the 14-month follow-up visit, a 1-cm faint pink macule persisted at the biopsy site.



**FIGURE 6.** A second biopsy was performed at the 14-month follow-up visit, showing changes consistent with lichenoid keratosis (LK) and regression of squamous cell carcinoma in situ. One small focus of partial-thickness epidermal atypia was identified, with remnants of an interface reaction as seen in LK.

of proangiogenic factors have been shown to occur. Cannabinoid treatment perhaps interferes or inhibits tumor growth on cutaneous skin cancers with its known effects of decreased vascularization and apoptosis of tumor cells. In this case, histologic evidence of an interface reaction (as seen in LK; Figure 6), after the application of cannabis oil supports its effectiveness in the treatment of SCCis.

### Conclusion

As demonstrated in this case report, a medical cannabinoid oil may be a promising adjunctive or alternative therapy in pa-

tolerated with minimal side effects.<sup>14</sup> Due to adverse reactions and a high cost of 5-FU and imiquimod, a cannabis-based oil might be an appealing alternative treatment option.

Endogenous cannabinoid receptors are widely expressed throughout the body and may be a therapeutic target, as they modulate activity in the central nervous system as well as peripheral sites such as the immune, cardiovascular, digestive, reproductive, and ocular systems.<sup>15</sup> Receptors CB<sub>1</sub> and CB<sub>2</sub> are expressed in both normal and tumor skin cells. In experimental models, apoptotic death can be seen in tumor epidermal cells with the activation of these receptors, while the viability of the normal epidermal cell remains unaffected.<sup>9</sup>

Emerging research shows that in the presence of cannabinoids, the immune system decreases the T-helper (Th)1 response and increases the Th2 response. Downregulation of T-cells by medical cannabinoids may have therapeutic implications in a number of conditions where the immune system is overactive. THC has been shown to affect the function of both macrophages and lymphocytes. Cell maturation leading to changes in functional characteristics within the bone marrow is suspected.<sup>16</sup>

The growth and development of SCC seems to rely on an early neovascularization in which vascular endothelial growth factor is an essential component.<sup>17</sup> In vivo and in vitro studies of cannabinoid-treated tumors showed an increased number of apoptotic cells along with impaired tumor vascularization.<sup>9</sup> Once cannabinoids were applied topically, altered blood vessel morphology and decreased expression

of patients with SCCis who prefer a topical treatment approach, including older patients who are poor surgical candidates. In this case, a topical cannabinoid oil, comprised mostly of THC was seemingly advantageous in treating SCCis as no side effects were reported, the treatment was non-invasive, and the oil represented a low treatment cost for the patient. However, we believe that large studies are required to clearly define the roles, efficacy, and applicability of a cannabis-based oil on SCCis.

### Consent

Written informed consent was obtained from the patient for publication of the case report and accompanying images.

### Acknowledgments

*The authors acknowledge the patient discussed in this case report.*

### References

1. Rogers HW, Weinstock MA, SR, Coldiron BM. Incidence estimate of nonmelanoma skin cancer in the US population, 2012. *JAMA Dermatol.* 2015;151(10):1081-1086.
2. Övermark M, Koskenmies S, Pitkänen S. A retrospective study of treatment of squamous cell carcinoma in situ. *Acta Dermato Venereol.* 2016;96(1):64-67.
3. Huang SJ, Hijnen D, Murphy GF, et al. Imiquimod enhances IFN-gamma production and effector function of T cells infiltrating human squamous cell carcinomas of the skin. *J Invest Dermatol.* 2009;129(11):2676-2685.

continued on page 49